

XTV-UGI by CCD high technology and hybrid and application idea technology

SYU supersonic wave laboratory Shuzou Arakaki

URL <http://syuzou.awk.jp/>

## 1 XTV-UGI Preparation knowhow

- ① A general barium preparation is high density in barium 200VW%
  - ② The quantity consumed is an amount of the use of a Japanese nationwide average of 150cc from 100cc.
  - ③ As for the barium preparation, the thing administered by about 30 stirs in the tap water of the normal temperature (About 25°C) before it uses it is recommended. Preservation is not recommended.
  - ④ The blowing agent fine-tunes at the right time according to the physique and uses 5g from 3.5g
- Note) Because taking is difficult, even an adult..blowing agent.. healthy recommends the taking method to have the idea. As for the purpose, it is important to put to the mind swelling the stomach by air.
- ⑤ It is general not to use the medicine of the buscopan etc. that stop the peristaltic motion in the routine study and the health examination.

Note) The foreign body reaction action is admitted in the human body in the experience as for barium, and the peristaltic motion tends to be activated when it is for drinking. Moreover, because liquidity is high, the particle has the feature that the shift from the stomach to small intestines quickens in addition in the medicine made of high density barium therefore very greatly.

## 2 UGI Beginning of inspection

- ① The blowing agent from 3.5 to 4g is administered by the water of 5cc. → To swallow the water of 5cc by the addition at a dash, it administers it to drop the blowing agent to the stomach at once when finishing drinking.  
The platform for photography has the barium glass in the left hand of getting on, the contralateral hand (right hand) does the handrail, and the grasp positioning is done firmly.
- ② The air image of an epigastrium is confirmed by seeing through before it begins to take a picture.  
At this time, when the air content is a little (progress defect of the stomach), the firing medicine is added in the proper quantity.


### 3 Imaging of taking a picture

#### Anatomy



The stomach front  
Stomach orifice of the stomach and [\*\*].  
Part  
Stomach body central part stomach small  
bay side  
Gastric angle  
Duodenal cap  
The lower side of stomach body  
Front yard part and pyloric duodenum  
descent leg

Stomach orifice of the stomach and [\*\*].  
Part  
It walls it in front of the stomach body  
Chubu University bay side.  
Duodenal cap  
Horizontal part of duodenum




LAO45

Stomach orifice of the stomach and [\*\*]. Part  
 Body of stomach central part small bay side  
 where the most effective physique to paint  
 barium on anterior wall area can be guessed  
 Wall after stomach body Chubu University  
 bay side  
 It walls it in front of the stomach body  
 central part small bay side.  
 Duodenal cap



Latelal

Horizontal part of duodenum  
 Stomach orifice of the stomach and [\*\*]. Part  
 Wall after central part of stomach body  
 Wall before central part of stomach body  
 Duodenum [fa-ta]?Wall after nipple  
 department former garden and pyloric



Axial

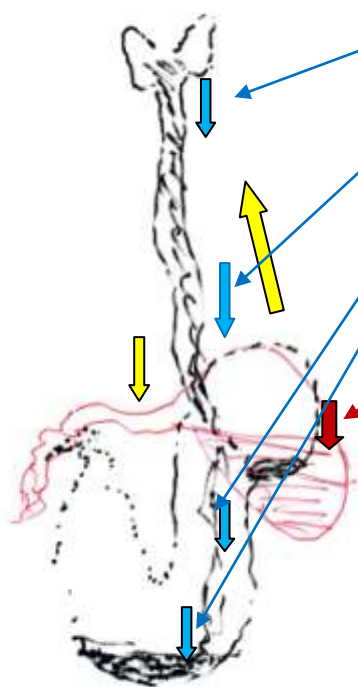
Stomach orifice of the stomach and [\*\*]. It walls it in front of the part.  
 Wall after central part of stomach body  
 Stomach orifice of the stomach and [\*\*]. Wall after wall front yard part and pyloric after part  
 Duodenum [fa-ta]?Papillary edge

## Taking a picture

### 3 Beginning of taking a picture

3.5-gram blowing agent is administered and (30cc) is drunk by one barium item.→The pursuit confirmation from the gullet to the stomach is done by seeing through.

The glass is put on the tray→The right, the left, and the waist are smeared in [\*\*sha] while knocking down the bed of half rotation (The stomach is applied to the bed, and the handrail on both sides is gripped firmly) seeing through stand and barium is smeared on the twist anterior wall center evenly slowly greatly.



When the first unit is drunk, the barium migration is pursued to see through without fail. It completely confirms it to the stomach until settling.

A blue arrow is shape of a normal stomach.

Barium does flow [\*\*\*\*] to [\*\*] Takashi part like this for the cow corner stomach.

Moreover, air is exhausted as a reft without swelling the gastric antrum. Even if the firing medicine is administered again here, it doesn't become a problem solving.

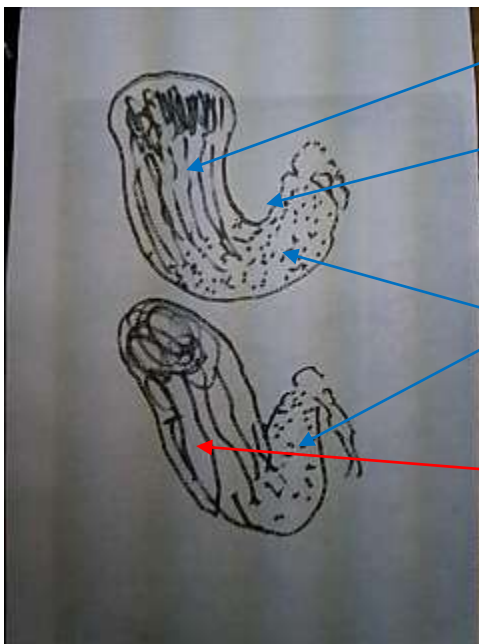
Coping process Barium is dropped to the gastric antrum and it corrects it to the shape of a normal stomach by the weight.

Note) Doing the routine study in a short time ..smooth.. ..this first confirmation.. becomes possible. The amount and the taking method knowhow of the blowing agent that should be added by executing it faithfully

at each inspection as a confirmation before it begins to inspect it can be acquired. The beginner especially rotates to [\*\*sha] the purpose is the solid to understand and confirms the space solid construction.

① Prone position-anterior wall of stomach double Enhancement(It is a positioning in the front as for the gastric angle.)

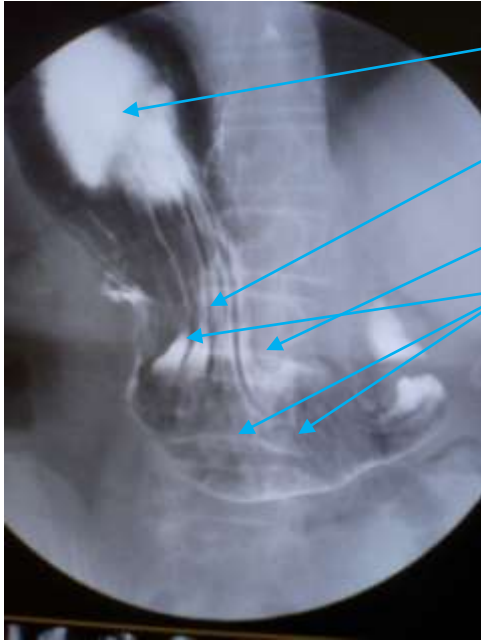
Note) An impossible taking a picture promptly discontinues, devises the roll in that case at lie on one's back stomach double [tsukukage], smears the anterior wall barium enough, and takes a picture of the anterior wall and the posterior wall simultaneously because it is difficult for the cow corner stomach to paint barium on the anterior wall. It executes it by taking a picture 678.



Barium has been painted in a lamella as for the wall before central part of the stomach body. The stomach corner part is the front (The note bed is required and the inclination of 30° or more is required).

The wall is getting on of uniform barium for the light make-up in front of the front yard.

After a note large bay side, the wall is clearly described.



It moves while smearing the anterior wall a small amount of barium.

The adhesion of barium is a heavy getting on.

Description of stomach corner part

Getting on of barium is comparatively good, and judges it for the prompt for cow corner stomach etc. of which it takes a picture to moderation discontinuance because it influences the following taking a picture harmfully when aiming at perfection important.

To the lie on one's back title in right surroundings after it takes a picture→  
The bed is set up. (prone position in case of cow corner stomach as it is)

Note) Changing position's knack. The table rolls easily when doing by a slight [ta] title (About ten degrees). The position of the handrail also notes enough (The elbow bends gripping the handrail).

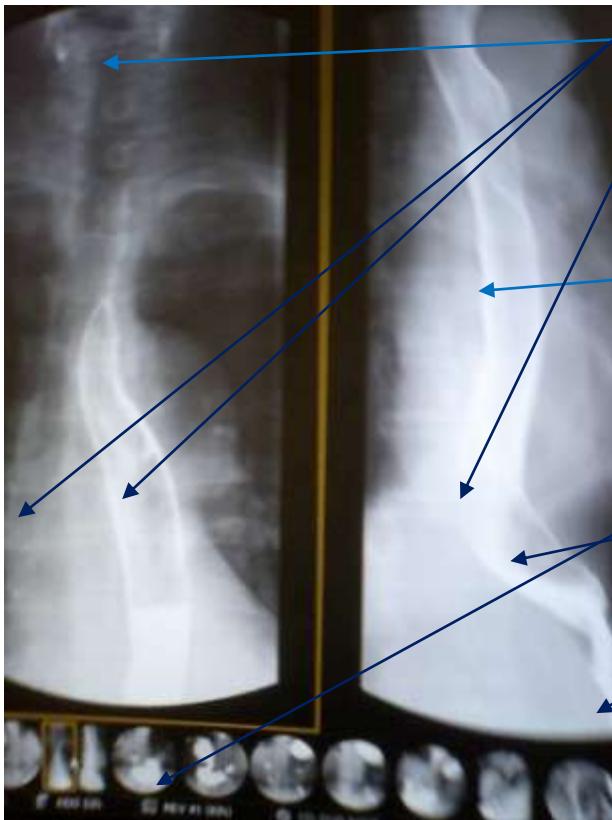
Possession a lot of ..glass.. barium ..unit.. contains it, and it issues instructions and it ..riot.. drinks the left hand the additional administering 1.5-gram blowing agent. At this time, the taking a picture timing is guessed because it confirms it by seeing through (The epiglottis moves and barium will pass in two seconds).

②The above part gullet filling front taking a picture

The technique sees the movement of the larynx and ascertains the barium street timing.

③Doubleenhancement lower esophagus the first diagonal title (diagonal title from which EC junction is observed on true side)

Note) Execute an additional taking a picture when you admit the artefact and the opinion that worries to the diagnosis.



Epiglottis

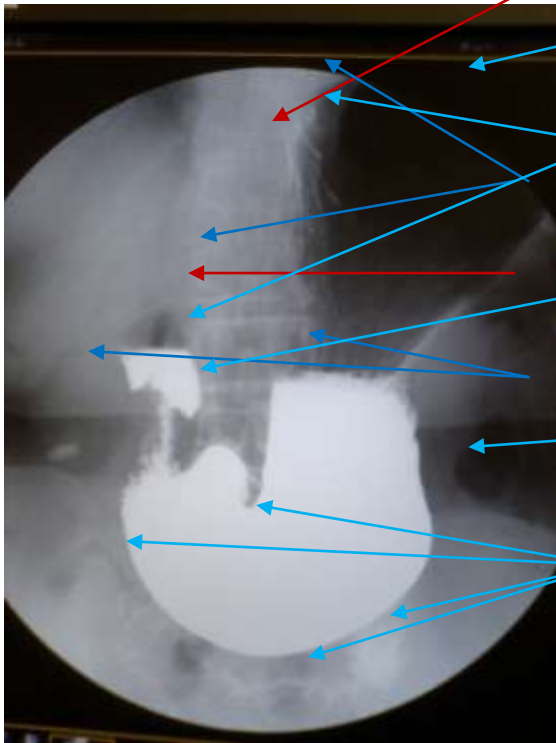
Bow and tangential direction

Excellent double contrast radiography of central part gullet

The junction is a double contrast radiography of open mouth excellent .

Increase and supplement the number of shots when you do not obtain an enough progress image.

④ Upright positioning filling (The gastric angle is put out).



It is not necessary to put it forcibly within the range of taking a picture because there are a lot of lacking things usually.  
A near edge can be observed enough with air contrast.  
The shape of the duodenum is confirmed.  
Tightening artefact of rubber  
No do [shi] ..the front.. ..the lack and... the most important a near edge of the stomach corner part

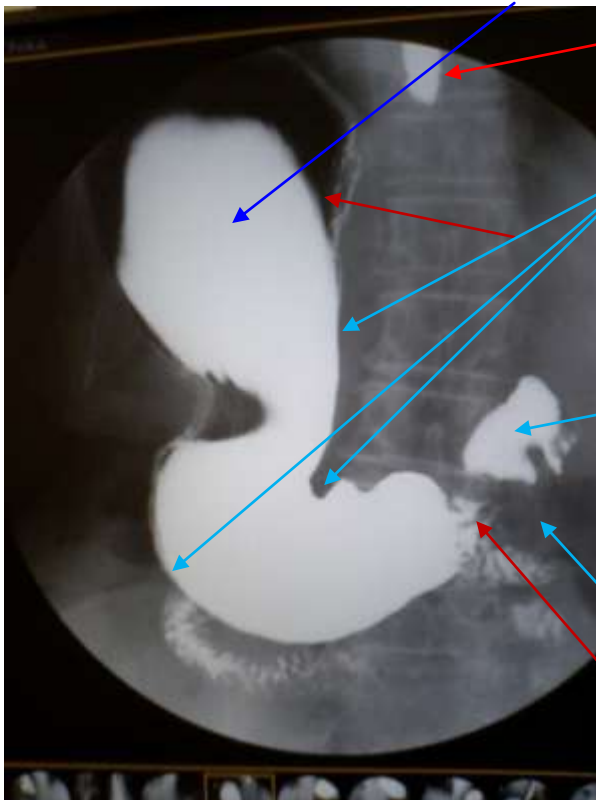
As for the image taken a picture of, the peristaltic motion is controlled by the pressure of barium and air. It is tightened in the [jutsukoromo] pair of trousers rubber band you do not consequentially recommend pyloric of you because it disturbs the changing position and the roll work though you should move the pair of trousers because it has shrunk.

It is a very unsightly noise for ..numerating.. doctor that imege is done. It rotates in the latter half of taking a picture and the stomach is applied to the bed.→The bed is horizontally knocked down a little in the right.

→Fine-tuning the physique is aimed at to prevent the outflow as much as possible while confirming the barium outflow to the duodenum by seeing through, barium is shaken, and the tunica mucosa ventriculi is flushed while the bed is being knocked down (Intense movement is not directed and the thing comfortably done is preferable).



⑤ Prone Position Filling (The gastric angle is put out. )



The backflow to the gullet is admitted.

As for a near edge, it is described smoothly and plainly

The barium filled in the ball can be possible the thing returned to the stomach by setting up the bed as it is as a prone position, and reduce coming in succession by the following double contrast radiography by the work.

It is seen a rubber negligible tightening it.

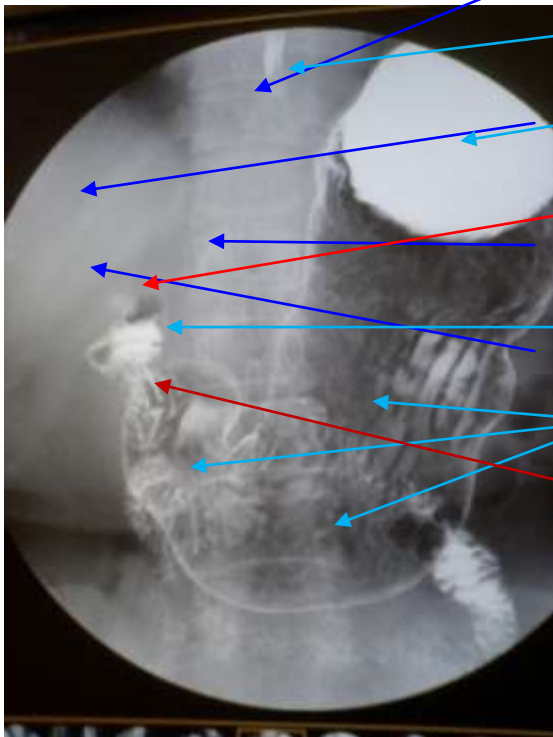
It is seen ..defective progress it...

At this time, because barium flows out to the duodenal cap, the bed is put up as it is and barium is returned to the stomach. → The physique is converted into turning up by the right rotation in a head high place of about ten degrees in the bed. → Barium in the pylorus front yard part coming in → The bed is knocked down to a head low place about ten degrees.

(Trying the barium paint is done whenever it confirms by seeing through and the barium adhesion is bad. ) Or, it smears in the duodenum repeating the half rotation roll the prone position and about three times by right surroundings in lie on one's back title → left surroundings while knocking down the bed and barium is smeared on the anterior wall and the posterior wall preventing barium from flowing out (It is not in a hurry and rolls slowly).

Note..excessive..duodenum..air..send..decubitusposition..physique..maintenace..avoid..one..initial..take a picture..safe..roll..crazy..become..careless..reft..put out..changing position..signal..slowly..panic..have..smooth..do..direct.

⑥ Lie on one's back title The stomach front Double contrast radiography (The gastric angle is put out. ) Head low place. Ten degrees



Barium and this that remains are ..diagnosis.. worthy. the gullet Barium filled in cardia of stomach

The gallstone is admitted, and it is thought important laboratory findings. Barium that shifts to duodenum descent leg

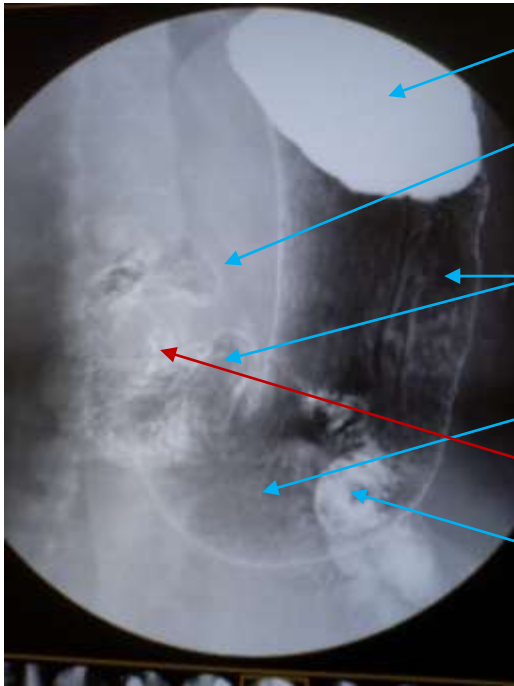
As for both anterior walls and the posterior walls, barium is painted.

It is seen ..defective progress it...

The photograph can be honest, and the age group be expected by the shape of the stomach in this photograph and the outline of the bone. As for the photograph, when the age is taken into consideration, [pu-a-] is guessed to be an enough photograph.

It twists one's body at the waist to the setting up ..bed.. the right by about five degrees, and the barium of the cardia of stomach is reshuffled to pyloric. → It twists one's body at the waist to the left and barium is returned to the cardia of stomach. At this time, barium is smoothly comfortably smeared evenly while confirming the area of the moving tunica mucosa ventriculi by seeing through. It is enough by about three times.

⑦ Lie on one's back title Stomach LAO Double contrast radiography



Barium filled in cardia of stomach

It is a smearing double contrast radiography in the duodenal cap enough as for barium (There are a lot of insufficient paint of the anterior wall).

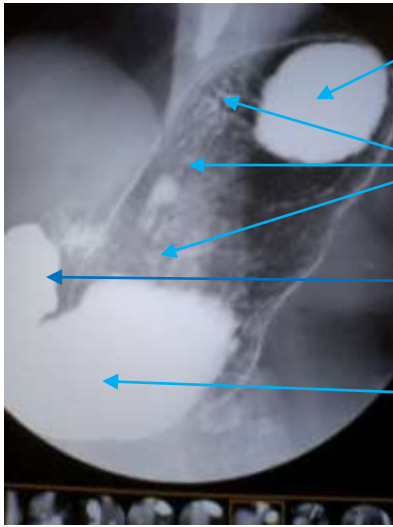
This area is a description of the anterior wall side.

It is described as the posterior wall is plain.

It is seen ..defective progress it...  
Coming in succession and this of the duodenum are disregarded.

It twists one's body at the waist to the right, and the barium of the cardia of stomach is reshuffled to pyloric. → It twists one's body at the waist to the left and barium is returned to the cardia of stomach. At this time, barium is smoothly comfortably smeared evenly while confirming the area of the moving tunica mucosa ventriculi by seeing through.

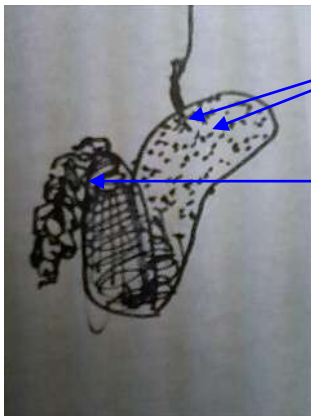
⑧ Lie on one's back title Stomach Central part small bay sidewall RAODouble contrast radiography



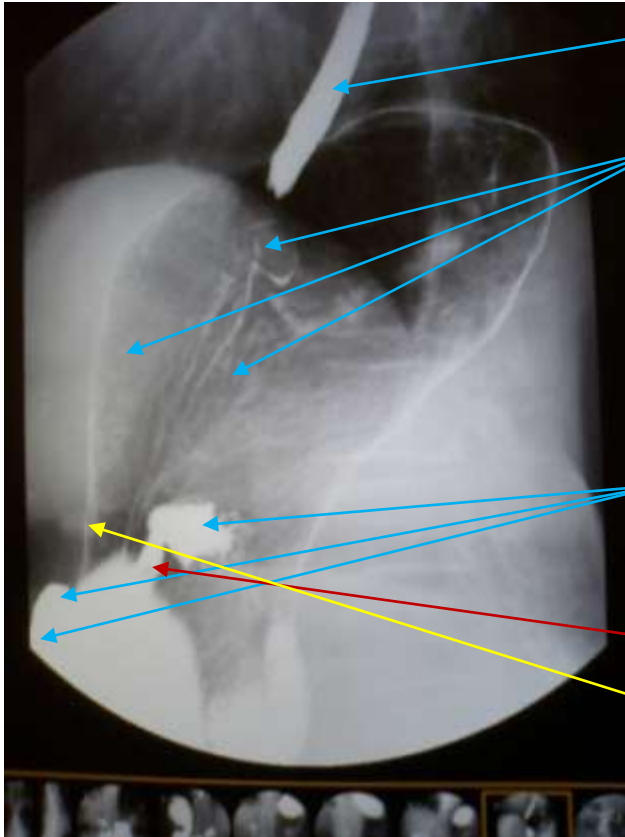
Barium of cardia of stomach  
 Barium is smeared enough from the anterior wall of stomach on the small bay side and it takes a picture.  
 It progresses enough and it is seen.  
 Barium distributed to pyloric

The right is made strong while painting barium on the junction in a head low place and all the bariums of the cardia of stomach are moved to pyloric (barium outflow multi [i] to small intestines that the left surroundings one rotation is preferable).

⑩ Lie on one's back title cardia of Stomach RAODouble contrast radiography



Therefore, it takes a picture of a left rotation (Barium flows out easily to the duodenum usually) to paint barium on the junction at the end.  
 Barium flows to the duodenum. At this time, it observes by pressure and it takes a picture of the duodenum. A possible CCD method reduces the inch, the spatial resolution is improved, and it takes a picture of the construction of free taking a picture timing by not using the film taking a picture technique such as the division taking a picture and doing one piece shot every time. There is no change even if the spatial resolution expands for FPD.



Barium that flows backward to gullet and proof that shifts barium enough to junction surroundings Barium is smeared enough on the junction surroundings.

An important opinion can be observed and the thing not lacking it is important though it is a filling image.

It is seen ..defective progress it... The gallbladder stone is admitted, and the mucous membrane wall defective progress generation has occurred in the area where it touches the gallbladder at the high rate.

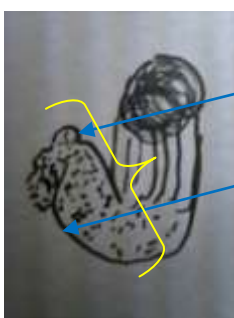
One piece shot ends and advances to the spot taking a picture (spot radiography) by this.

Note) It is necessary to improve the image quality only by can take a picture the spot, to take a picture, and the enlarging radiography to be preferable.

### Beginning of spot taking a picture

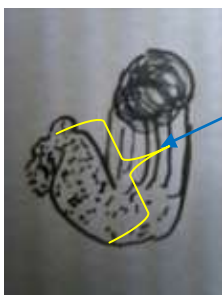
Is it basically Lie on one's back title cardia of StomachRAODouble contrast radiography The barium of the duodenal cap is advanced and taking a picture is advanced while coming in [\*\*] because it starts after taking a picture. → The changing position converts it into the double contrast radiography by knocking down the bed 45 times in the right at the diagonal title level and using breath while expanding and contracting the stomach.

⑪ Double contrast spot of wall after diagonal the first in lie on one's back title duodenum ball title



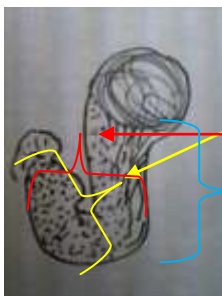
The duodenal cap is a double contrast radiography to progress enough.  
The flowing extent of barium is good for the duodenum descent leg.  
It is a diagonal title of the sending double contrast radiography, pyloric, and the extent that doesn't come in succession if possible as for air.

⑫ Double contrast spot of Pylorus wall after diagonal the first in lie on one's back title



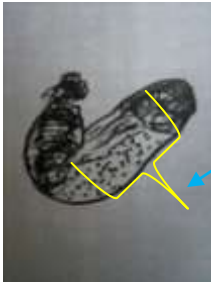
Diagonal title of duodenal cap and extent that doesn't come in succession.  
The barium that slightly remains is observed, and it is not, leaves, and you may observe your mucous membrane by the thin layer method by using this. whether it is

⑬ Pylorus wall The front ⑭ Stomach corner part ⑮ Stomach Wall after central part



Pylorus wall The front  
Stomach corner part  
Stomach Wall after central part

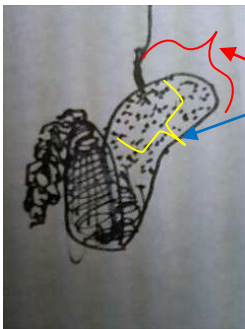
⑩ The Stomach Wall small bay front



The Stomach Wall small bay front

It drops from the orifice of the stomach to the pylorus, and the paint barium takes a picture of barium from the pylorus against the orifice of the stomach according to timing where drying up exists.

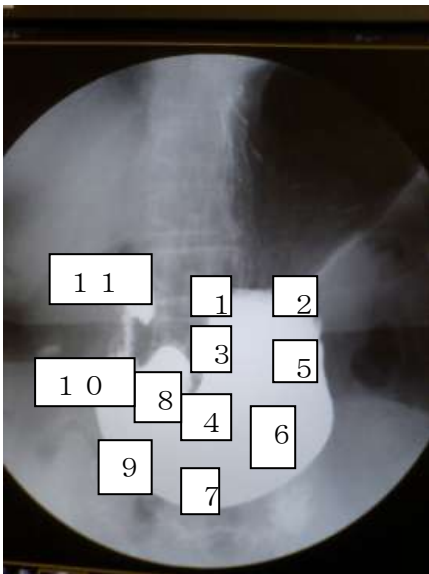
⑪ Surrounding stomach body upper Junction ⑫ The wall double make shadow in front of a part small bay on the stomach body.



The stomach body upper Junction surrounding lamella method

The wall double make shadow in front of a part small bay on the stomach body. Area where touch stimulus is received when street flows like food etc.

Pressure taking a picture ⑬ Pressure taking a picture ⑭ Pressure taking a picture ⑮ . . . . .



The pumping is pressed ..the entire stomach.. in numerical order, it observes evenly, and any taking a picture records 1 , 5 , 4 , 8 , 1 1 ..it not is... As for the seen box-frame construction, there are a lot of cases of the anterior wall because pressure is chiefly excellent in the description of the anterior wall change to a morbid state. Change to a morbid state is described in the posterior wall lamella method taking a picture though it can be confirmed to change to a morbid state the posterior wall by strong pressure ..the upheaval and concave...

**Note) The pressure cylinder is not moved up and down and right and left though presses.**

# Knowledge that undertakes X rays of stomach inspection and technology that should acquire it

1 About the characteristic of the use medicine

① About the buscopan action

The buscopan will demonstrate the effect for the intramuscular injection in about five minutes.

The effect is demonstrated at tens of seconds at the vein injection.

The thing of the buscopan not used is abundant in the screening taking a picture and the stomach checkup.

② About [baritogen] HD used the characteristic now of barium

[Baritogen] HD is a drug product that reduces the Stickiness degree and in consideration of liquidity for a high density coarse particle.

It is assumed that the normal temperature tap water that is safe water with the most much recommendation anywhere immediately before use is added, it mixes by 30 stirs or less, and it administers it. Liquidity and the [nebatotono] degree character might change obviously by stirring too much and putting making and it become difficult with a steady barium painting.

③ About the bubble cancellation liquid

Because the addition of the bubble cancellation liquid deteriorates the adhesion of barium, the method of not doing the addition use is recommended.

Make the barium manufacturer and the factory the same and do the use amount by the manufacturer recommendation when using it.

④ About the blowing agent

As for administering the blowing agent, administering by water is the most preferable. It swallows with 5cc at a dash and the method that quickly reaches the stomach at once by the water of 5cc is recommended because it foams without reaching the stomach enough in past 5cc. As for the increase of 5cc, because barium is high density, the influence is negligible.

Taking with barium

The stomach can be efficiently swollen by taking the blowing agent with barium.

Because getting on of driven thing and barium ..point that should be noted.. foams efficiently ..worsening of some.. for a few minutes even of the foam completion, it is an overdosed thing. **The swelling of the stomach is recommended to be confirmed by about 3g at the time of the barium administering.**



When administering it, the attention observation is done enough generation and defective feelings of the left as 5g administering is opposite because it interferes to the causing inspection. It explains measures before it inspects it beforehand because can it control when the breath is endured when the left goes out, air be drunk, and the air omission prevention by the left be returned. As for not the worrying amount but an extra additional dosage, there are a lot of obtaining the result of your should would being better not to do though flat from the nose is often seen.

## 2 Operation acquisition of device

### 1 About the image quality

The spatial resolution changes into DDI of the CCD auto iris method according to view.

The flat panel method is 175 $\mu$ m dot element space resolution now.

As for the CCD method, the amount of 15 $\mu$ m of the dot element space resolution data becomes 100 times about 10 $\times$ 10 at six inches 12 inches in 30 $\mu$ m6 inch.

The viewing 10M half-size size case monitor is calculated with the one that becomes 300 $\mu$ m element

The CCDII method is the afterimage phenomenon and shows a weak tendency to movement and the breath blur. Moreover, an irradiation squeezing technique that is weak to the halation and proper is required.

### 2 About the console operation

The top and bottom of the platform for photography and the left-right locomotor are done with the lever of the right hand.

Occurring operation knocked down and the pressure cylinder in the platform for photography are scanned by the left hand.

ON OFF of seeing through is done with the foot switch of the right leg.

Irradiation field Squeezing is adjusted by the left hand.

The instruction such as the changing positions is left legs ON OFF because it uses the mike.

Because it is not an exaggeration to say that the skill of the left hand scanning will grip the key to take a good photograph, let's forge the left hand scanning.

### 3 About the taking a picture dose

The dose is possible because of the II method by a little amount (1/1000 compared with FD).

Seeing through can be adjusted lower by the digital pulse method.

The timer sound rings so far every five minutes.

It is thought that it is necessary to do a necessary seeing through confirmation when thinking from these data.

#### 4 About the flow of the inspection

Examining before it inspects it in an interview→Selection of method of administering barium and examination medicine→Explanation of flow of changing position and inspection→Inspection beginning→The movement of [\*\*sha] is contemplated while seeing seeing through like the forecast of the adjustment taking a picture timing at bed Irradiation field Squeezing is adjusted , the respiratory control, the irradiation squeezing, and the table position etc. administering barium by the unit while slowly confirming it by seeing through and converting the physique into the Sue mousse comfortably and expected imaging progresses. The irradiation squeezing scanning of the bed is basically reduced as much as possible.

A spatial, solid structure is understood by seeing through, barium is smeared on a target wall, and it confirms it.

Purpose..accomplish..understand..simple..clear..instruction..safety..voluminous..changing position..reft..endure..have..a few seconds..rest..image..efficiently..inspection..progress..have..both

hands..foot..compound..for..scanning..technique..always..safety..consideration..artefact..measures..always..head..inside..settle down..rotate..have.The skill improves by the considered training.